




**INFORMATION BRIEF (RAPID REVIEW)**

**MICROWAVE ABLATION AND  
INTERVENTIONAL  
EMBOLISATION FOR  
MALIGNANT TUMOUR OF  
KIDNEY WITH METASTASES TO  
LUNGS, LYMPH NODES AND  
PERITONEUM**

Malaysian Health Technology Assessment Section (MaHTAS)  
Medical Development Division  
Ministry of Health Malaysia  
**019/2023**



## **DISCLAIMER**

This information brief is a brief report, prepared on an urgent basis, to assist health care decision-makers and health care professionals in making well-informed decisions related to the use of health technology in health care system, which draws on restricted review from analysis of best pertinent literature available at the time of development. This report has not been subjected to an external review process. While effort has been made to do so, this report may not fully reflect all scientific research available. Other relevant scientific findings may have been reported since the completion of this report. MaHTAS is not responsible for any errors, injury, loss or damage arising or relating to the use (or misuse) of any information, statement or content of this report or any of the source materials.

Please contact [htamalaysia@moh.gov.my](mailto:htamalaysia@moh.gov.my) if further information is required.

Malaysian Health Technology Assessment Section (MaHTAS)  
Medical Development Division  
Ministry of Health Malaysia  
Level 4, Block E1, Precinct 1  
Government Office Complex  
62590, Putrajaya  
Tel: 603 8883 1229

Available online via the official Ministry of Health Malaysia website: <http://www.moh.gov.my>

**SUGGESTED CITATION:** Tengku Noor Farhana TK and Izzuna MMG. Microwave Ablation and Interventional Embolisation for Malignant Tumour of Kidney with Metastases to Lungs, Lymph Nodes and Peritoneum. Ministry of Health Malaysia: Malaysian Health Technology Assessment Section (MaHTAS); 2023. 12 p. Report No.: 019/2023

**DISCLOSURE:** The author of this report has no competing interest in this subject and the preparation of this report is entirely funded by the Ministry of Health Malaysia.

## **TITLE: MICROWAVE ABLATION AND INTERVENTIONAL EMBOLISATION FOR MALIGNANT TUMOUR OF KIDNEY WITH METASTASES TO LUNGS, LYMPH NODES AND PERITONEUM**

### **PURPOSE**

To provide brief information on the efficacy/effectiveness, safety and cost-effectiveness of microwave ablation and interventional embolisation for malignant tumour of kidney with metastases to lungs, lymph nodes and peritoneum following a request from the Director of Medical Practice Division, Ministry of Health Malaysia.

### **BACKGROUND**

Kidney cancer happens when there is abnormal cell growth in either of the kidneys or both.<sup>1</sup> It was the ninth most common cancer among men and the 14th most common among women. The most common type of kidney disease was renal cell carcinoma (RCC), predominantly about 90% of the cases. This included different types of RCC such as clear cell RCC (70%), papillary RCC (10 - 15%) and chromophobe RCC (5%).<sup>2</sup>

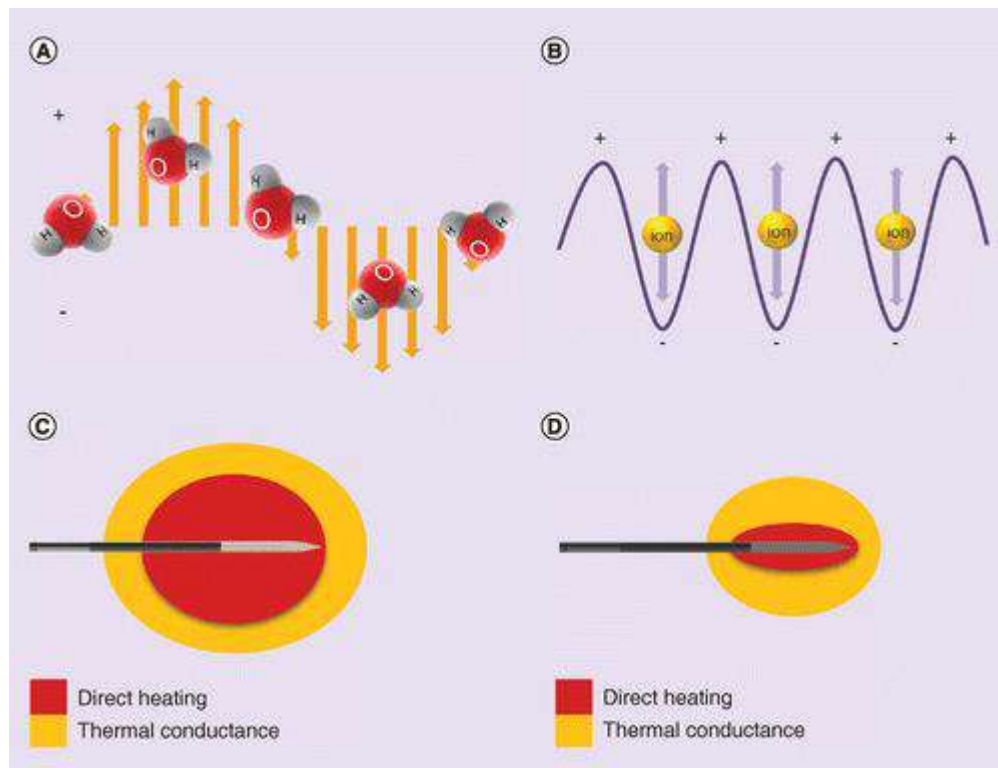
The incidence of kidney cancer has increased throughout the years. The first worldwide age-standardised ratio (ASR) reported for kidney cancer was 7.1/100,000 in 1975, which steadily increased to a peak of 16/100,000 in 2008. In 2020, an estimated 431,288 new cases of kidney cancer were detected globally with the worldwide ASR reported as 4.6/100 000. The incidence varies widely throughout all continents, with generally higher rates in Asia (36.6%), Europe (32.1%) and North America (17.8%). The median age at diagnosis of kidney cancer was approximately 75 years. Kidney cancer contributed to 179,368 deaths worldwide (115,600 men and 63,768 women), with a calculated global ASR rate of 1.8/100 000. In Asia, the highest incidence of kidney cancer was in Western Asia (ASR=4.1 per 100,000) followed by Eastern Asia (ASR=4.0 per 100,000). Both regions also had the highest ASR value for mortality rate (ASR=1.8 per 100,000).<sup>2</sup> According to the Malaysia Cancer Registry Report 2012 - 2026, it was reported that this cancer was the 12<sup>th</sup> most common cancer among males with ASR of 2.1 per 100,000 population and the 18<sup>th</sup> most common cancer among females with ASR of 1.0 per 100,000 population.<sup>3</sup>

Most of the kidney cancer detected was small low-grade tumours. However, up to 17% of RCC had distant metastases at the time of diagnosis. Lungs, bone and brain were the most frequent sites of distant metastases.<sup>4</sup> In Malaysia, more than half of kidney cancer cases (52.9%) were diagnosed at stage IV which represents the involvement of distant metastases.<sup>3</sup> Therefore, different modalities have been discussed in the management of kidney cancer, both localised and metastases. Guidelines had recommended that nephrectomy (either radical or partial) is

the mainstay of surgical treatment for kidney cancer. However, evidence has evaluated the potential of thermal ablation, including microwave ablation (MWA), in the management of kidney cancers.<sup>5</sup>

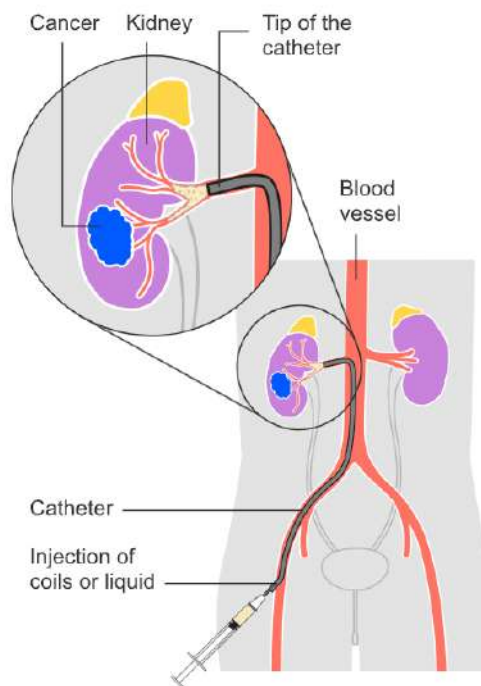
### Technical features

MWA is one of the thermal ablation techniques recently introduced for the management of kidney cancer. It uses high electromagnetic waves with frequencies of 915 or 2450 MHz using energies varied between 1 - 100 W through concentrated energy on one or multiple antennas placed in the tumour. Tumour cells are damaged by the mechanism of creating a thermal field by rotation of dipole water molecules, producing heat and causing tissue necrosis in solid tumours. The antennas can be placed either by a percutaneous laparoscopic or open approach under general anaesthesia. The number of antennas used depends on the size and location of the tumour. The penetration depth of the energy can be adjusted by the frequency of the energy source.<sup>6</sup> Literature has found that MWA is potentially beneficial with its higher tissue heating, deeper penetrance, adaptable power and shorter time settings characteristics.<sup>7</sup> Each ablation may take about 10 to 30 minutes, and the entire procedure typically takes about one to three hours.<sup>8</sup> Figure 1 briefly showed the differences of underlying mechanism of action and heat transfer between MWA and radiofrequency ablation (RFA).<sup>9</sup>



**Figure 1: The underlying mechanism of action and heat transfer for MWA (A & C) and RFA (B & D)**

The local control of primary kidney cancer is of particular clinical importance to avoid local treatment failure. Therefore, to have better control of high-risk tumours, intervention embolisation such as transarterial embolisation (TAE) is used in combination with other modalities.<sup>10</sup> The aim of embolisation is to identify and interrupt the blood flow of all arterial branches intended for the renal tumour compartment. The procedure is done according to the Seldinger technique. Firstly, the access point is by puncturing the femoral artery at the fold of the groin, then a 6 Fr introducer is placed and continued with mapping of renal vascularisation by intra-aortic injection of contrast media in a 4 - 5 Fr angio-catheter positioned in the aortic lumen at the level of T12 - L1. Each arterial branch intended for the renal compartment was then catheterised. Embolisation of the main renal artery was carried out under fluoroscopic control with an Amplatzer plug (cylindrical mesh in self-expanding nitinol) of a maximum diameter of 8 mm or with helical coils and gel foam in the initial portion of the main renal artery. Accessory arterial branches were embolised according to the operator's preference by coils, a sclerosing agent or particles.<sup>11</sup> Different embolisation materials (e.g. ethanol, iodized oil, resorbable gelatin sponge and polyvinyl alcohol particles) with sizes between 150 and 250  $\mu\text{m}$  and 500 - 700  $\mu\text{m}$ , or a combination, were used for selective or super-selective embolisation.<sup>10</sup> The whole procedure takes about 30 minutes to a few hours depending on the number of blood vessels targeted for the intervention.<sup>12</sup>



**Figure 2: The procedure of arterial embolisation as part of the management of kidney cancer<sup>13</sup>**

**EVIDENCE SUMMARY**

A total of 563 titles were retrieved from scientific databases such as Medline, EBM Reviews, EMBASE via OVID, PubMed and from general search engines [Google Scholar and US Food and Drug Administration (USFDA)], using the search term; kidney cancer, kidney malignancy, renal cell carcinoma, metastases, MWA and interventional embolisation. The last search was conducted on 19 December 2023. Six articles were found to be relevant and included in this review which comprised of two meta-analyses, three systematic reviews and one non-randomised trial. These studies assessed the effectiveness and safety of MWA and/or interventional embolisation as the treatment of kidney tumours with/without metastases. Articles on the registration and cost of MWA and interventional embolisation were also included in this review.

**EFFICACY/ EFFECTIVENESS****Effectiveness on Microwave Ablation**

A systematic review consisting of two cohort studies with 348 stage T1b RCC patients was conducted by Cazalas G et al. in 2021 assessing the long-term oncologic efficacy of MWA compared with radical or partial nephrectomy. Quality assessment was not mentioned in this review. Multiple databases were used to search for evidence using the appropriate search terms. The review described that both studies achieved 100% technical efficacy after the second percutaneous MWA ablation. One study found that MWA had lower 5-year local recurrence rate-free survival than radical nephrectomy ( $p < 0.02$ ) not for partial nephrectomy. However, there were no significant differences in the local recurrence rates, cancer-specific survival rate, cancer-specific mortality rate and progression to metastatic disease between MWA and radical or partial nephrectomy. Furthermore, MWA was shown to have a shorter median length of hospitalisation than partial nephrectomy (1 day vs 4 days) and radical nephrectomy (1 day vs 4 days) ( $p < 0.0001$ ).<sup>14</sup>

Another systematic review by Prins FM et al. in 2017 aimed to summarise the efficacy, safety and outcome of alternative therapeutic methods available including MWA, focusing on nephron-sparing treatment for T1 RCC. Ten studies comprising 498 patients were identified with levels of evidence between 2b and 4 according to the Oxford Centre for Evidence-based Medicine Levels of Evidence 2009. Based on the review, MWA was reported to be less affected by the heat-sink effect which resulted in reaching higher intra-tumoral temperatures and less ablation time compared with RFA. A study revealed that MWA was significantly better with a higher percentage of ablation success in tumours  $< 4$  cm (100% success) compared to  $> 4$  cm (75% success). Few studies revealed the need for a second ablation session due to residual tumours. The review also reported that there was no significant effect on estimated glomerular filtration rate (eGFR) and post-procedural creatinine levels. However, some studies described



a small decline in kidney function. In terms of recurrence, the recurrence-free survival rate was 62% to 100% with one patient having a recurrence of metastatic disease. MWA was also reported to have 92 - 100% cancer-specific survival rate.<sup>6</sup>

Castellana R et al. conducted a meta-analysis in 2023 on the effectiveness of MWA compared with RFA and cryoablation (CA) for the treatment of renal tumours without any assessment of the progression to metastatic conditions. Ten retrospective cohort studies were identified which comprised 2258 procedures. Overall, five studies had moderate risk of bias and the other five studies had serious risk of bias. Based on the analysis, MWA showed lower local recurrences than non-MWA (OR=0.31, 95% CI 0.16 to 0.62). There were no significant differences in the primary technical efficacy rate (defined as the percentage of tumours successfully eradicated following the initial procedure), overall survival rate and cancer-specific survival rates. Another sub-analysis comparing MWA with CA showed that MWA had fewer local recurrences rate (OR=0.30, 95% CI 0.11 to 0.84). No outcomes were significantly differences in a sub-group analysis with T1 renal tumours only.<sup>7</sup>

### **Effectiveness on Interventional Embolisation**

There was no evidence found on the effectiveness of interventional embolisation with MWA. However, three articles evaluated the effectiveness of interventional embolisation in renal tumours. A multicentre non-randomised trial was conducted by Alegorides C et al., 2020 to assess the feasibility and outcomes of immediate preoperative renal artery embolisation (IPRAE) before complex nephrectomy for locally advanced RCC with/without inferior vena cava thrombus (IVCT). Forty-six patients received the intervention while 99 patients received complex nephrectomy with/without IVCT alone considered as the controls. Patients were not randomised and blinded for the above procedures. All patients were accounted for in the analysis. Based on the trial, the results showed that the intervention had lower mean intraoperative blood loss ( $p=0.03$ ). Multivariate analysis revealed that IPRAE reduced the risk of perioperative bleeding ( $p=0.02$ ). However, there was no significant difference between the two groups in terms of mean postoperative hospital stay.<sup>11</sup>

Sommer CM et al. in 2017 described a systematic review of the literature of seven case series among 60 patients with significant comorbidity and high risk for ablation-associated haemorrhage using TAE as an add-on to percutaneous RFA. The review only used one database to search for the relevant studies answering the objectives of the review. Quality assessment of primary studies was conducted using the Downs and Black checklist, however no report on the final outcomes of the assessment. The review reported that the combination was effective in the treatment of renal tumours as it showed that the local tumour control rate was 100%, metastasis-free survival rate was 90%, cancer-specific survival rate was 100% and overall survival rate was 90%.<sup>10</sup>

In terms of localised tumours, a meta-analysis by Lin L et al. in 2019 evaluated renal function, complications and tumour sizes of renal angiomyolipomas (AMLs) after TAE. Multiple databases were used to conduct an extensive search of the articles that had reported on the outcomes of the intervention. Thirty cohort studies that fulfilled the criteria had been identified. These studies included 653 patients diagnosed with renal AMLs. Using the Agency for Healthcare Research and Quality Cross-Sectional/Prevalence Study Quality checklists, 18 studies scored 11 points, six studies scored 10 points, three studies scored 9 points and the other three studies scored 8 points. In the review, 32.0% of patients were treated by urgent TAE for spontaneous ruptured renal AMLs while others were indicated as symptom relievers or received embolism prophylactically. However, it was noted that the course of embolisation explained in the studies was inconsistent and the embolisation agents used were varied. Based on the analysis, the mean blood urea nitrogen was increased after 1-week of embolisation and remained higher than baseline after 6-month post-embolisation. Similarly, mean eGFR was noted to reduce after three days of intervention but increased after 2-month post-intervention. The percentage of reduction in size for the AMLs post-intervention was 30.0% (95.0% CI 16.0% to 44.0%). All analyses were compared with baseline values.<sup>15</sup>

## **Organisational**

Only two guidelines mentioned the use of MWA in renal tumours. The American Urological Association guideline mentioned that the management of renal mass and localised renal cancer was still investigational.<sup>16</sup> However, later guidelines by the Asian Conference on Tumor Ablation described that MWA was found to be safe and effective for the management of RCC. It also required a shorter time compared to other treatment modalities. However, the complication rates of MWA were similar to other modalities. This guideline recommends the use of MWA especially for large RCC (>3 cm).<sup>5</sup>

A guideline by Society of Interventional Radiology described the use of pre-ablative embolisation of the arteries supplying the RCC in order to reduce bleeding complications, eliminate heat sink effects or attempt to shrink the tumour pre-ablation.<sup>17</sup>

MWA and interventional embolisation are registered under the USFDA and Medical Device Authority Malaysia (MDA) since 2019, however they are not specifically indicated for the management of kidney cancer.<sup>18-20</sup> Under MDA, MWA is registered with the indication for ablation of soft tissue particularly for lung and liver cancers.<sup>19</sup>

## **SAFETY**

### **Safety on Microwave Ablation**

Cazalas G et al. in 2021 reported that there was no ablation-related death among all studies and the complication rates were not significantly different between MWA and radical or partial



nephrectomy. One study reported that the reduction of eGFR was significantly lower in the MWA compared with radical nephrectomy.<sup>14</sup>

In a review by Prins FM et al. (published in 2017), the complication rates of using MWA varied between 0% to 60%. The reported complications were classified into low-grade complications (haematuria, numbness, flank pain, thermal injury, urine fistula and subcapsular renal haemorrhage) and high-grade complications (urinoma, retrained foreign body, urine leakage and abscess formation requiring drainage, hydrothorax, pleural effusion and bowel injury). The other two studies reported no complications from the procedure.<sup>6</sup>

Castellana R et al., 2023 also reported that there were no significant differences between MWA and non-MWA in terms of major complications, overall complications and changes in eGFR. In a subgroup analysis comparing only MWA with RFA, fewer overall complications were seen in MWA (OR=0.60, 95% CI 0.38 to 0.97). Another sub-analysis showed that MWA had fewer overall complications compared with CA (OR=0.49, 95% CI 0.28 to 0.85).<sup>7</sup>

### **Safety on Interventional Embolisation**

The non-randomised trial by Alegorides C et al., 2020 showed that there was no significant difference in the rates of overall complication between IPRAE and control (11% vs 21%,  $p=0.30$ ).<sup>11</sup>

Out of 60 patients receiving TAE as an add-on to percutaneous RFA, two patients reported to have abscesses and three with hematomas.<sup>10</sup>

Lin L et al., 2019 also reported that the rate of post-embolisation syndrome (PES) was 54.0% (95.0% CI 36.6% to 70.4%) with 4.4% having major complications. The major complications included renal abscesses, femoral arterial pseudoaneurysms, urinary tract infection, renal insufficiency, acute respiratory distress and pleural effusion. In this review, one died from haemodynamic failure due to a femoral false aneurysm and renal abscess.<sup>15</sup>

### **COST-EFFECTIVENESS**

There was no evidence assessing cost-effectiveness of MWA and interventional embolisation in kidney malignancy. A retrospective cohort study by Yu J et al., 2020 described that the total cost for MWA was much cheaper than laparoscopic partial nephrectomy [REDACTED].<sup>21</sup> A pre-post study described that the cost for an applicator of MWA per patient was [REDACTED] excluding tax.<sup>22</sup> According to Medigence, 2022, the cost for MWA for endometrial disease was between [REDACTED].<sup>23</sup>

## CONCLUSION

Available evidence showed that MWA may have beneficial effects on the treatment of kidney cancer. MWA was found to be effective with a lower local recurrence rate with fewer complications and shorter duration of treatment compared with other modalities. However, it was reported that there was no significant difference in primary technical efficacy rate, cancer-specific survival rate, cancer-specific mortality, overall survival rate and progression to metastatic disease. Interventional embolisation was found to be useful in addition to the main treatment (e.g. nephrectomy or thermal ablation) to reduce bleeding. However, no evidence was found on the safety and effectiveness of the combination of MWA with interventional embolisation.

## REFERENCES

1. Cleveland Clinic. Kidney Cancer (accessed online on 19 December 2023). Available from: <https://my.clevelandclinic.org/health/diseases/9409-kidney-cancer-overview>
2. Bukavina L, Bensalah K, Bray F, et al. Epidemiology of Renal Cell Carcinoma: 2022 Update. *Eur Urol*. 2022;82(5):529-542.
3. Ministry of Health Malaysia. Malaysia National Cancer Registry Report 2012-2016. Putrajaya; 2019.
4. Capitanio U, Montorsi F. Renal cancer. *Lancet*. 2016;387(10021):894-906.
5. Park BK, Shen S-H, Fujimori M, et al. Asian Conference on Tumor Ablation guidelines for renal cell carcinoma. *Investig Clin Urol*. 2021;62(4).
6. Prins FM, Kerkmeijer LGW, Pronk AA, et al. Renal Cell Carcinoma: Alternative Nephron-Sparing Treatment Options for Small Renal Masses, a Systematic Review. *J Endourol*. 2017;31(10):963-975.
7. Castellana R, Natrella M, Fanelli G, et al. Efficacy and safety of MWA versus RFA and CA for renal tumors: A systematic review and meta-analysis of comparison studies. *Eur J Radiol*. 2023;165.
8. Boston Medical Center. Microwave Ablation (accessed online on 19 December 2023). Available from: <https://www.bmc.org/content/microwave-ablation>
9. Kim C. Understanding the nuances of microwave ablation for more accurate post-treatment assessment. *Future Oncol*. 2018;14(17):1755-1764.
10. Sommer CM, Pallwein-Prettner L, Vollherbst DF, et al. Transarterial embolization (TAE) as add-on to percutaneous radiofrequency ablation (RFA) for the treatment of renal tumors: Review of the literature, overview of state-of-the-art embolization materials and further perspective of advanced image-guided tumor ablation. *Eur J Radiol*. 2017;86:143-162.
11. Alegorides C, Bigot P, Hardwigsen J, et al. Immediate preoperative renal artery embolization in the resection of complex renal tumors (UroCCR-48 Reinbol study). *Int Urol Nephrol*. 2021;53(2):229-234.

12. The Center for Vascular Medicine Patient First Awareness Program. Embolization Procedure: What to Expect and FAQ (accessed online on 19 December 2023). Available from: <https://www.cvmus.com/vascular-procedures/embolization-procedure-what-expect-and-faq#:~:text=A%20doctor%20may%20use%20a,minutes%20to%20a%20few%20hours>.
13. Cancer Research UK. Blocking the blood supply for kidney cancer (renal artery embolisation) (accessed online on 19 December 2023). Available from: <https://www.cancerresearchuk.org/about-cancer/kidney-cancer/treatment/renal-artery-embolisation>
14. Cazalas G, Jambon E, Coussy A, et al. Local recurrence and other oncologic outcomes after percutaneous image-guided tumor ablations on stageT1b renal cell carcinoma: a systematic review and network meta-analysis. *Int J Hyperthermia*. 2021;38(1):1295-1303.
15. Lin L, Li X, Guan H, et al. Renal function, complications, and outcomes of a reduction in tumor size after transarterial embolization for renal angiomyolipomas: a meta-analysis. *J Int Med Res*. 2019;47(4):1417-1428.
16. Campbell S, Uzzo RG, Allaf ME, et al. Renal Mass and Localized Renal Cancer: AUA Guideline. *J Urol*. 2017;198(3):520-529.
17. Gunn AJ, Parikh NS, Bhatia S. Society of Interventional Radiology Quality Improvement Standards on Percutaneous Ablation in Renal Cell Carcinoma. *J Vasc Interv Radiol*. 2020;31(2):195-201.e3.
18. MDA. Registered Medical Device Search: embolization (accessed online on 19 December 2023). Available from: <https://mdar.mda.gov.my/frontend/web/index.php?r=carian%2Findex&CompletedApplicationAllmdrSearch%5BglobalSearch%5D=embolization>
19. MDA. Registered Medical Device Search: microwave ablation (accessed online on 19 December 2023). Available from: <https://mdar.mda.gov.my/frontend/web/index.php?r=carian%2Findex&CompletedApplicationAllmdrSearch%5BglobalSearch%5D=microwave+ablation>
20. USFDA. Search: Microwave Ablation (accessed online on 19 December 2023). Available from: <https://www.fda.gov/search?s=microwave+ablation>
21. Yu J, Zhang X, Liu H, et al. Percutaneous Microwave Ablation versus Laparoscopic Partial Nephrectomy for cT1a Renal Cell Carcinoma: A Propensity-matched Cohort Study of 1955 Patients. *Radiology*. 2020;294(3):698-706.
22. Genson PY, Mourey E, Moulin M, et al. Image-guided percutaneous microwave ablation of small renal tumours: short- and mid-term outcomes. *Quant Imaging Med Surg*. 2015;5(5):649-55.
23. MediGence. Microwave Endometrial Ablation cost in Malaysia (accessed online on 19 December 2023). Available from: <https://medigence.com/hospitals/general-surgery/microwave-endometrial-ablation/malaysia>

**Prepared by**

Dr. Tengku Noor Farhana Tengku Khalid  
Public Health Physician  
Senior Principle Assistant Director  
Health Technology Assessment Section (MaHTAS)  
Medical Development Division  
Ministry of Health Malaysia

**Reviewed by**

Dr. Izzuna Mudla Mohamed Ghazali  
Public Health Physician  
Deputy Director  
Health Technology Assessment Section (MaHTAS)  
Medical Development Division  
Ministry of Health Malaysia

**19 February 2024**